

Short report

HAYCOCKNEMA PERPLEXUM: AN EMERGING CAUSE OF PARASITIC MYOSITIS IN AUSTRALIA

Luke J Vos, Thomas Robertson, Enzo Binotto

Abstract

Haycocknema perplexum is a rare cause of parasitic myositis, with all cases of human infection reported from Australia. This case involved an 80-year-old Queensland wildlife carer, who presented with muscle weakness, mild eosinophilia and creatine kinase elevation. This case supports an association with native animal contact and highlights the debilitating nature of this infection. *Commun Dis Intell* 2016;40(4):E496–E499.

Keywords: *Haycocknema perplexum*, parasitic myositis, nematode, native animals, Australia

In 1998, Dennett et al. described a new nematode that causes myositis, *Haycocknema perplexum*.¹ Male and female *H. perplexum* live inside individual muscle fibres and are 25 to 45 µm in diameter and 300–500 µm long.¹ The published literature contains 8 reports of *H. perplexum*, 4 from Tasmania and 4 from northern Queensland.^{1–4} This report describes the 9th known case, an 80-year-old female from northern Queensland (Table).

Case report

In October 2012, an 80-year-old wildlife carer was referred to the Cairns Hospital Infectious Diseases clinic with possible chronic Q fever and concerns regarding Lyme disease. She was prescribed rosuvastatin 10 mg at the time of review. She reported a progressive illness involving weakness of her arms and legs over the past 18 months, with functional limitation, such that she was unable to dress or shower independently. In addition, she reported a weight loss of approximately 5 kilograms over the previous 12 months. She reported no dysphagia, dysphonia, shortness of breath or myalgia.

The patient reported extensive native wildlife exposure, such as handfeeding puggles (juvenile echidnas) and caring for various marsupials including koalas, wombats, possums, wallabies and kangaroos. She owned a pet galah. She had sustained multiple tick bites in the past, but reported no direct cattle exposure. Her travel history was extensive, with past travel to South American, African and Asian countries. She reported previous, limited travel to Tasmania.

On examination, she appeared thin, with a weight of 59 kg. Diffuse, non-tender muscle wasting was evident in her upper and lower limbs. Cranial nerve examination was normal. Neurological examination of her limbs revealed symmetrically reduced power of 3 on 5, more marked proximally than distally. Knee jerks were present, with all other limb tendon reflexes absent.

Initial pathology investigations showed an eosinophilia ($0.7 \times 10^9/L$; reference range (RR), $< 0.4 \times 10^9/L$) and elevated serum creatine kinase (CK) level (270; RR, < 160). Levels of inflammatory markers were normal (erythrocyte sedimentation rate, 15 mm/h; RR 0–20; C-reactive protein, < 2 ; RR, < 5 mg/L). Q fever serology results were consistent with past exposure to Q fever.

Electromyography showed florid myopathic changes, with frequent spontaneous activity and occasional myotonic discharge from the proximal limb muscles. A muscle biopsy from the right anterolateral thigh showed an active inflammatory myopathy, with infiltration of the muscle by mononuclear cells and eosinophilic granulocytes and evidence of muscle injury. Three minute intracellular nematodes were identified in the limited biopsy provided (approximately 15 square mm in cross-sectional area in the cryostat sections). The nematodes were 16 microns in diameter in the plane of section and were characterised by a thin eosinophilic cuticle with surrounding sarcoplasmic retraction halo (Figures 1 and 2). Unfortunately, the tissue retained for electron microscopic examination did not contain any parasites. Although there were only limited nematodes for assessment, given the minute size, intracellular location, and association with eosinophilic myositis, a histopathologic diagnosis of *H. perplexum* parasitic myositis was made.

Initial management of this patient included cessation of rosuvastatin, with no steroids administered at any stage of her illness. She was treated with albendazole 400 mg twice daily for 12 weeks. She tolerated this treatment well, with normalisation of her eosinophil count and CK. Unfortunately, she experienced no functional improvement. Her limb muscle power continued to slowly decline, with increased assistance required for activities of daily living.

Table: Clinical and laboratory features of patients with myositis due to *Haycocknema perplexum*^{2,3,4}

Patient, age, sex	Place and year of diagnosis	Prior travel	Animal exposure	Duration of symptoms (years)	Dysphagia	Weakness	Weight loss (kg)	Peak CK level (U/L)*	Corticosteroids	Eosinophil count (x 10 ⁹ /L) [†]	Outcome
1. 33, F	Tasmania, 1994	Extensive, including northern Australia	Botanist, native animals and specimens	5	NA	‡	NA	3,294	Prednisolone prior to diagnosis – worsened	0.8	Good recovery, normal CK
2. 48, M	Tasmania, 1996	Extensive, including North Qld	Limited, field trip to Kakadu	1.5	§	§	7	1,586	Prednisolone prior to diagnosis –worsened	2.0	Good recovery
3. 61, M	North Qld, 2004	None in 20 years, born in Tasmania	Nil noted	3	§	§	NA	1,263	Yes	High	Died
4. 23, F	North Qld, 2005	Extensive travel in Australia	Nil noted	2	§	§	18	1,370	None	1.1	Weak, CK elevated at 6 years
5. 61, F	North Qld, 2006	Nil	Nil noted	2	‡	‡	NA	1,230	None	1.36	Weak, elevated CK at 6 years
6. 50, M	Tasmania, 2011	Extensive, no travel to North Qld	Native animals as pets, eaten bush meat	2	§	§	10	5,700	Prednisolone prior to diagnosis – marked deterioration	Normal	Good recovery, CK 470 U/L
7. 80, F	North Qld, 2012	Extensive, including Tasmania	Native animal carer	1.5	Nil	§	5	270	None	0.7	Weak, normal CK
8. 30, M	North Qld, 2014	Travel limited to North Qld	Nil	2	§	§	20	3,400	Prednisolone prior to diagnosis – new symptoms	1.24	Good recovery
9. 72, M	Tasmania, 2014	WA and Qld	Recreational hunter, eaten bush meat	Years	NA	‡	NA	2,082	Methyl-prednisolone prior to diagnosis	2.4	Good recovery

* Reference range (RR), <160 U/L

† RR, <0.4x 10⁹/L

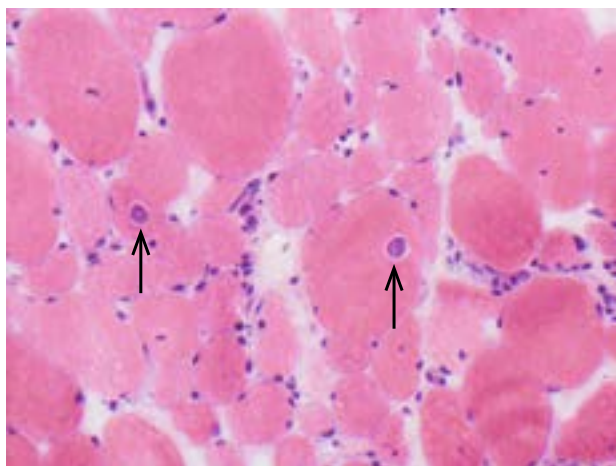
‡ Mild-moderate

§ Moderate-severe

CK Creatine kinase

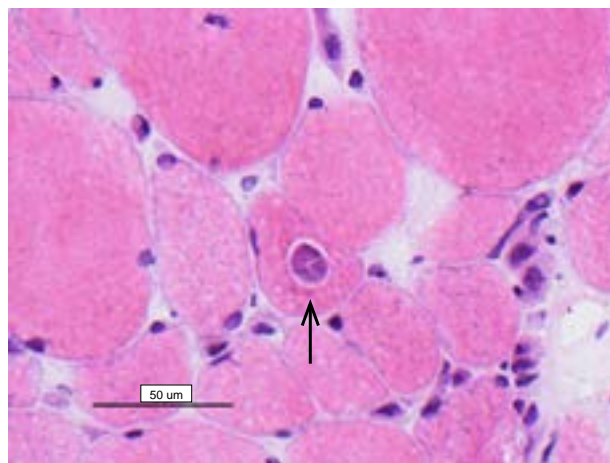
NA Not available

Figure 1: Myositis with two nematodes within myofibres



Cryostat section, haematoxylin-eosin stain, x 200 magnification

Figure 2: Transverse section of a nematode demonstrating a thin eosinophilic cuticle and sarcoplasmic retraction halo



Cryostat section, haematoxylin-eosin stain, x 400 magnification

Discussion

This report of *H. perplexum* infection in an 80-year-old female wildlife carer from northern Queensland represents the 9th known human case. This patient developed severe, functionally limiting limb weakness and a moderate weight loss of 5 kilograms. Laboratory investigations demonstrated a peripheral eosinophilia and mildly elevated CK. Electromyography showed florid myopathic changes, with the diagnosis confirmed on muscle biopsy. Unfortunately she did not improve with albendazole treatment, with continued decline in muscle power.

This case of *H. perplexum* shares several similarities with the previously reported accounts. This patient lived in the Tablelands Region of Far North Queensland, with a history of limited prior travel to Tasmania. Northern Queensland and Tasmania remain the only known locations of *H. perplexum* human infection.¹⁻⁴ She described sustained, close contact with native animals. Three of the previous 8 cases detail extensive animal contact.

Treatment recommendations for *H. perplexum* based on limited case reports include Albendazole 400 mg twice daily for 8 to 9 weeks, with a strong caution against steroid use.⁵ The patient in this case received 12 weeks of treatment, in view of good medication tolerance and uncertainty regarding optimal treatment duration. Given the limited information on the life cycle and transmission of *H. perplexum*, no infection prevention or control recommendations exist at present.

While *H. perplexum* is a suspected human zoonosis, the natural host remains unknown. *H. perplexum* had previously been assigned to the superfamily

Muspiceoidea.⁶ Muspiceoids have been isolated from Australian animals that include mice, bats, kangaroos, tree kangaroos, wallabies, pademelons, koalas and biting midge.⁶ However, new molecular findings have cast doubt on the earlier classification of *H. perplexum*, with further molecular evidence needed to elucidate phylogenetic relationships for other muspiceoid nematodes.⁴ A *Haycocknema*-like nematode has been identified in muscle fibres from a horse imported to Switzerland from Ireland.⁷

The difficulties and delays experienced in the diagnosis of *H. perplexum* raise the possibility of undiagnosed cases in the Australian community. The disease spectrum may include subclinical infection, in addition to severe cases that receive clinical attention. The report of an infection similar to *H. perplexum* in an Irish horse implies a greater potential distribution of human infection outside of Australia. Several of the reported cases suggest the importance of prolonged, close animal contact for acquisition of the parasite. At risk groups may include wildlife carers and veterinarians.

Potential areas for future research into *H. perplexum* include investigation into the natural host, mechanism of transmission and the life cycle. Recent definition of nuclear and mitochondrial gene markers for *H. perplexum* provide a molecular diagnostic tool for parasitic myositis in humans.⁴ In addition, polymerase chain reaction-based sequencing provides a useful research tool to survey potential reservoir animals or vectors, including horses, for *H. perplexum* and related genotypes.^{4,7}

This, the 9th reported case of human *H. perplexum* infection, adds to the limited clinical information on the presentation and course of this disease. It

supports the potential importance of close wildlife contact as a risk factor in those who develop clinical infection. The case highlights the serious nature of *H. perplexum* infection and the need for further biological and clinical research into this condition.

Acknowledgements

We wish to acknowledge the valuable assistance of Dr Andrew McNabb, Neurologist, Cairns Hospital.

There are no conflicts of interest to declare.

Author details

Dr Luke J Vos, General Physician, Cairns Hospital, Queensland

Dr Thomas Robertson, Pathologist, Pathology Queensland, Queensland

Dr Enzo Binotto, Infectious Disease Physician, Cairns Hospital, Queensland

Corresponding author: Dr Luke Vos, Department of Medicine, Cairns Hospital, The Esplanade, CAIRNS QLD 4870. Telephone: +61 7 4226 0000. Facsimile: +61 7 4226 6581. Email: Luke.Vos@health.qld.gov.au

References

1. Dennett X, Siejka SJ, Andrews JR, Beveridge I, Spratt DM. Polymyositis caused by a new genus of nematode. *Med J Aust* 1998;168(5):226–227.
2. Basuroy R, Pennisi R, Robertson T, Norton R, Stokes J, Reimers J et al. Parasitic myositis in tropical Australia. *Med J Aust* 2008;188(4):254–256.
3. McKelvie P, Reardon K, Bond K, Spratt DM, Gangell A, Zochling J, et al. A further patient with parasitic myositis due to *Haycocknema perplexum*, a rare entity. *J Clin Neurosci* 2013;20(7):1019–1022.
4. Koehler A, Spratt DM, Norton R, Warren S, McEwan B, Urkude R, et al. More parasitic myositis cases in humans in Australia, and the definition of genetic markers for the causative agents as a basis for molecular diagnosis. *Infect Genet Evol* 2016;44:69–75.
5. Australian Wildlife Health Network. Fact sheet: *Haycocknema perplexum*: Life-threatening disease of humans. 2008. Accessed on 20 July 2016. Available from: [https://www.wildlifehealthaustralia.com.au/Portals/0/Documents/FactSheets/Public%20health/Haycocknema%20perplexum%20Mar%202008%20\(1.1\).pdf](https://www.wildlifehealthaustralia.com.au/Portals/0/Documents/FactSheets/Public%20health/Haycocknema%20perplexum%20Mar%202008%20(1.1).pdf)
6. Spratt DM, Beveridge I, Andrews JR, Dennett X. *Haycocknema perplexum* n. g., n. sp. (Nematoda: Robertdolfusidae): an intramyofibre parasite in man. *Syst Parasitol* 1999;43(2):123–131.
7. Eckert J, Ossent P. *Haycocknema*-like nematodes in muscle fibres of a horse. *Vet Parasitol* 2006;139(1–3):256–261.